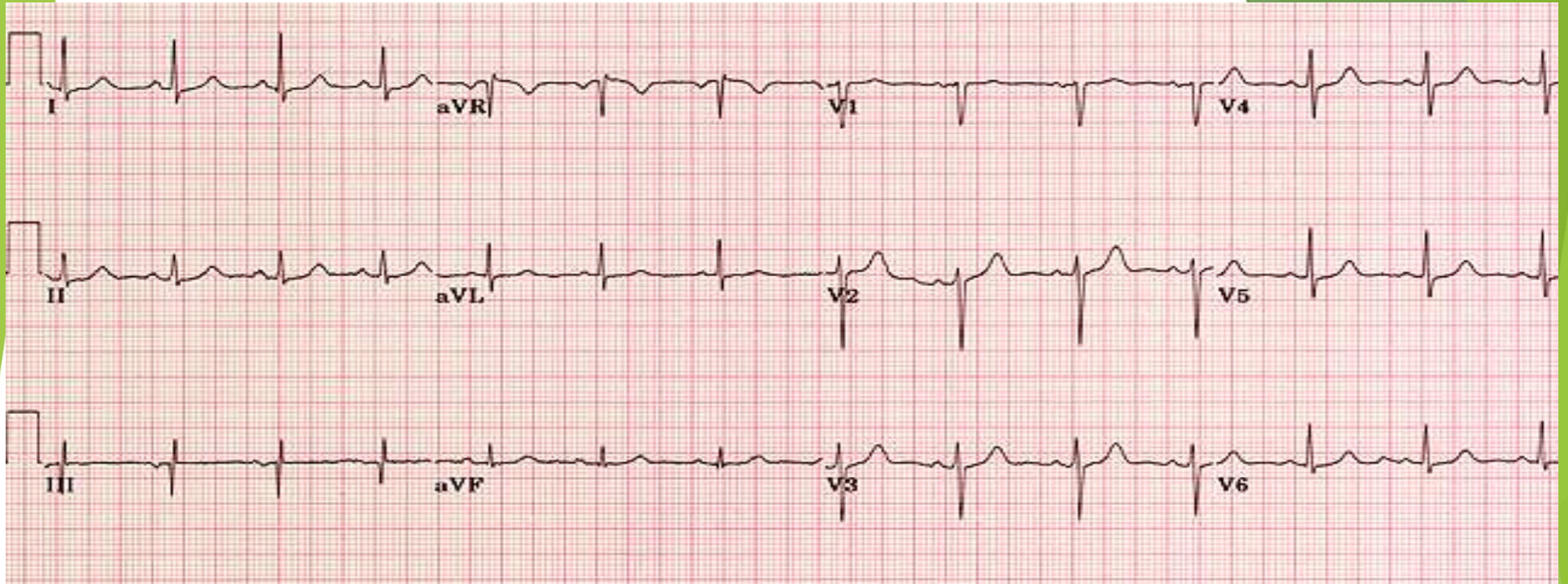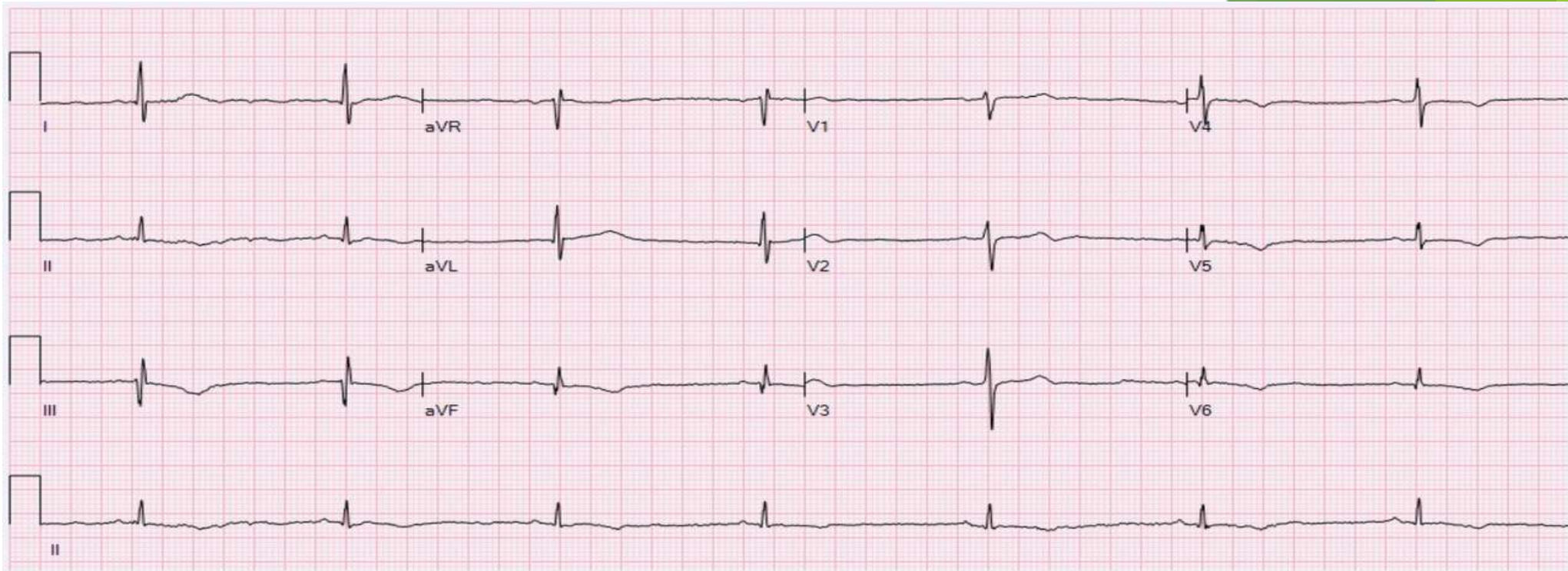
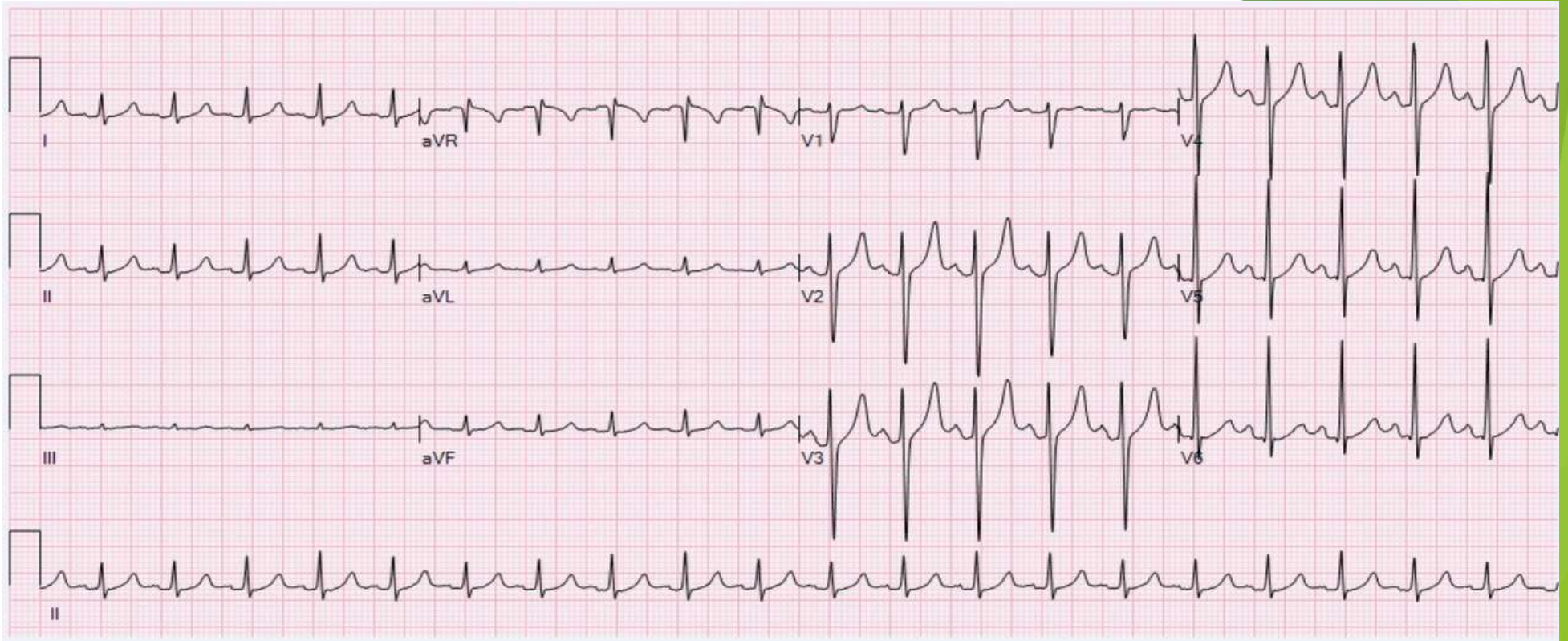


Normal sinus

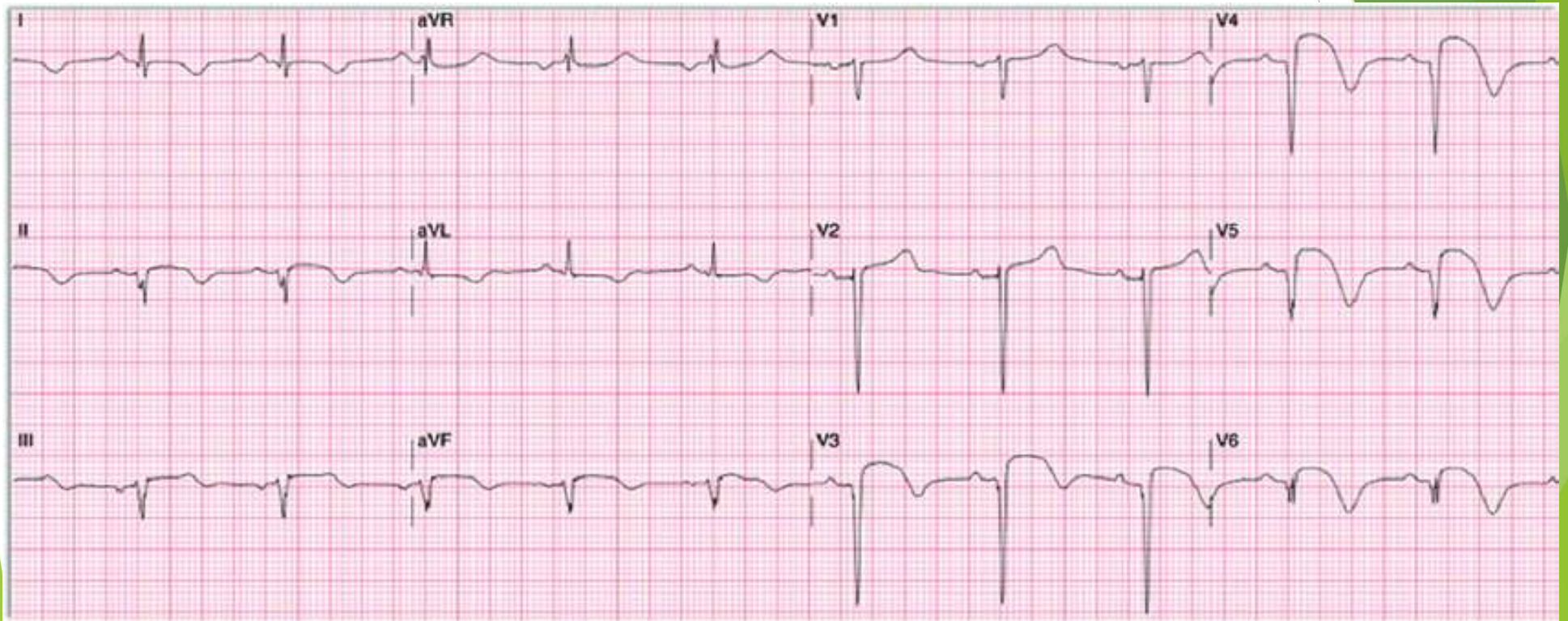


Sinus beradocardia

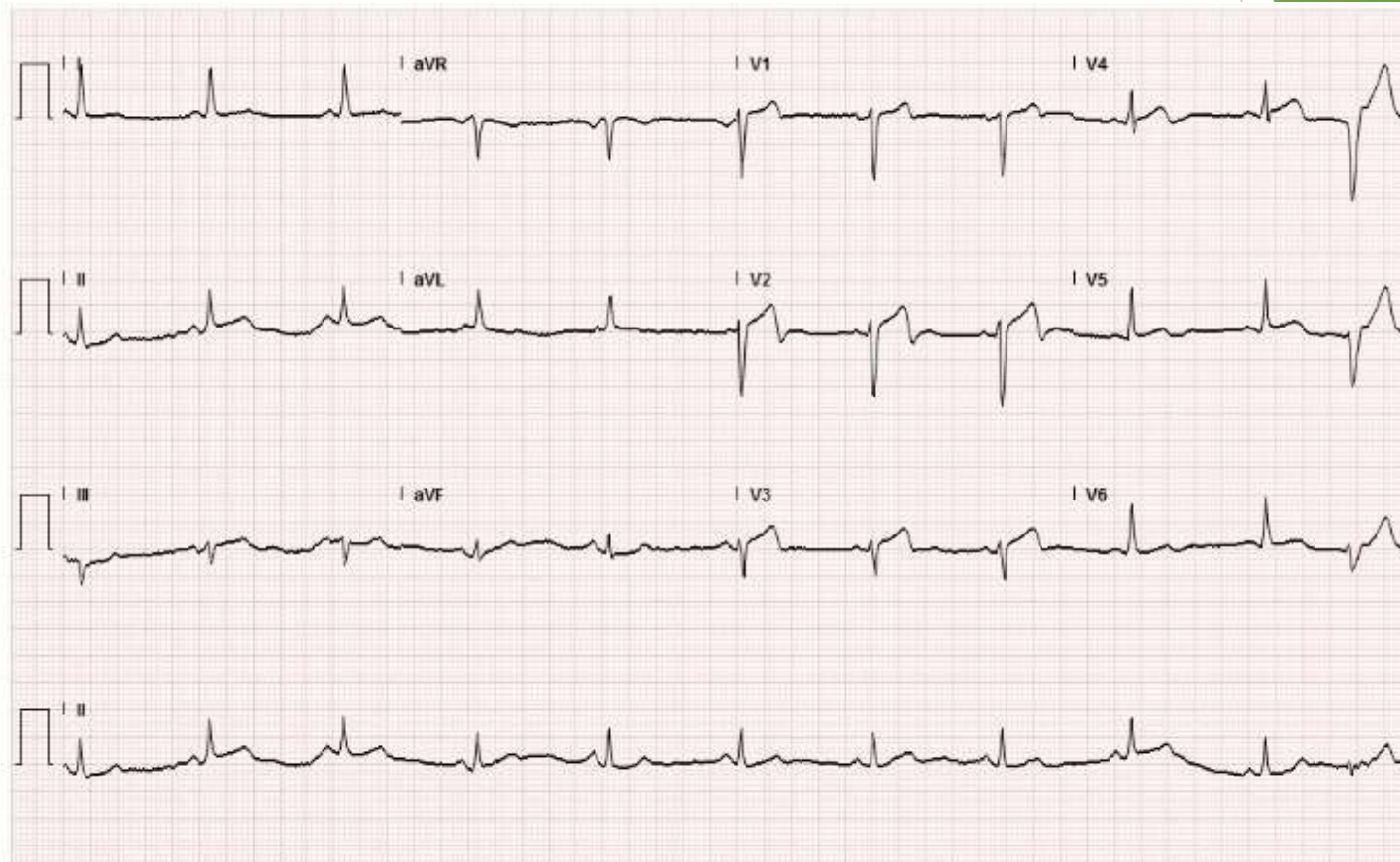


Sinua thacycardia

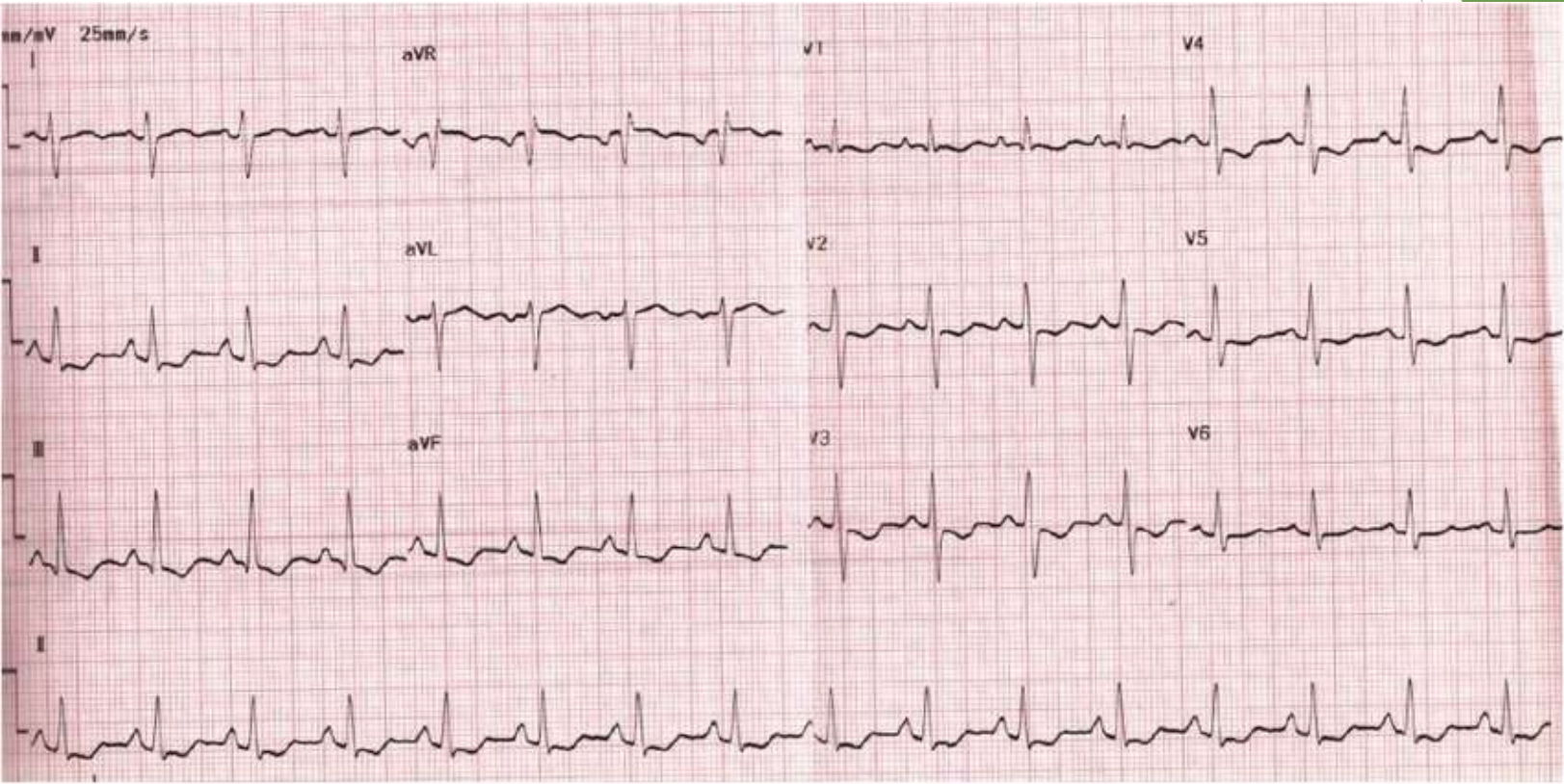
LAD



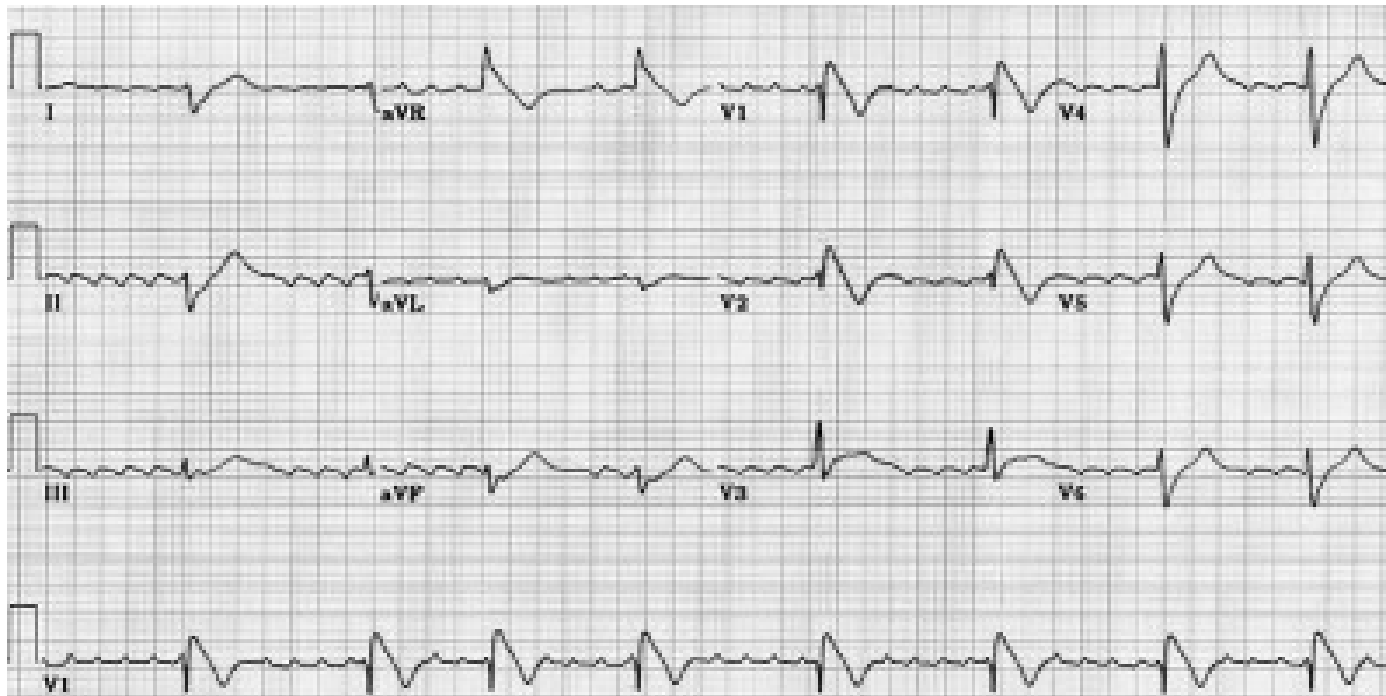
LAD 1



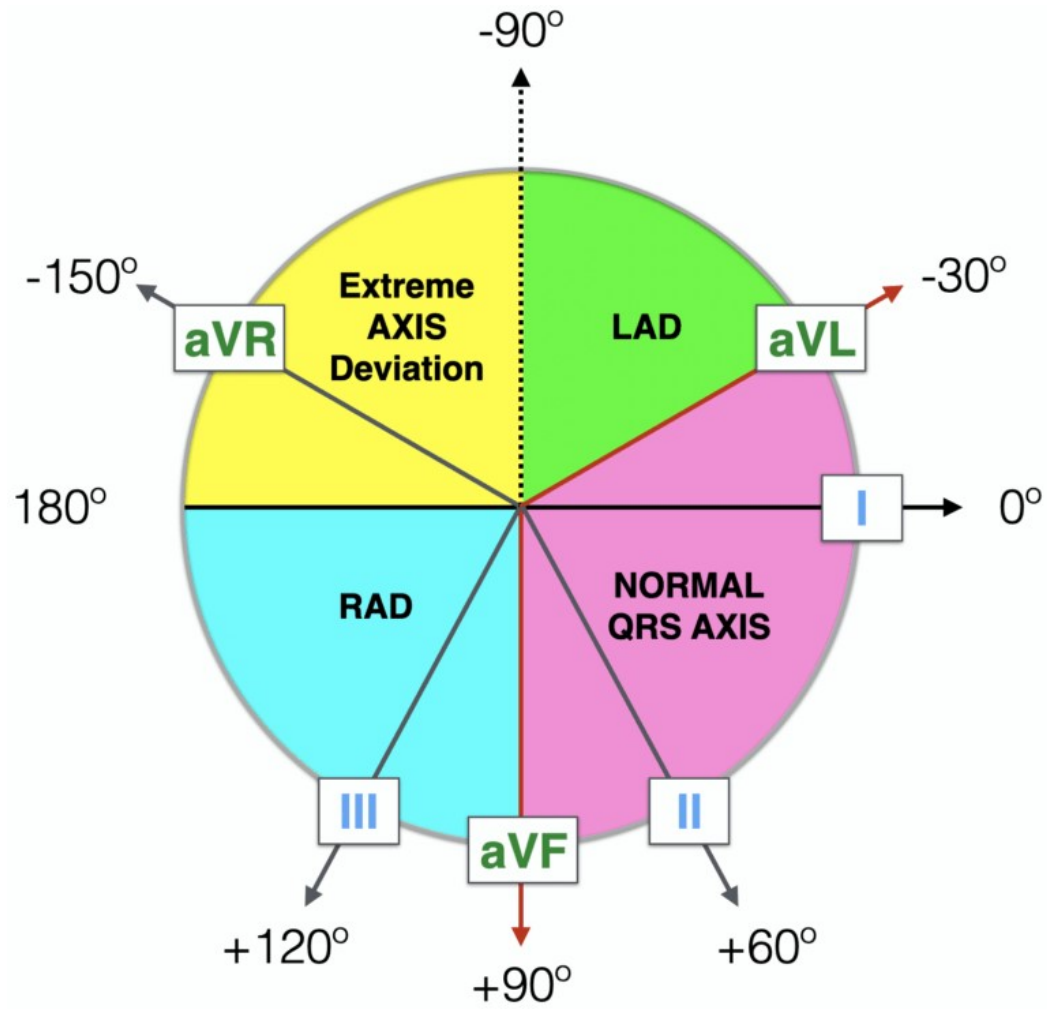
RAD



EXTRIM



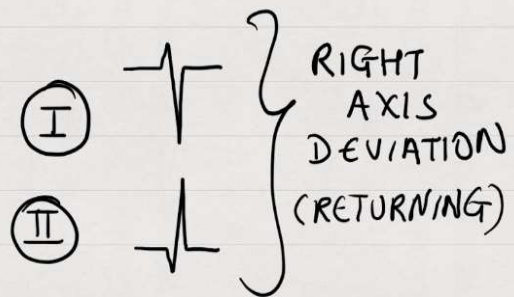
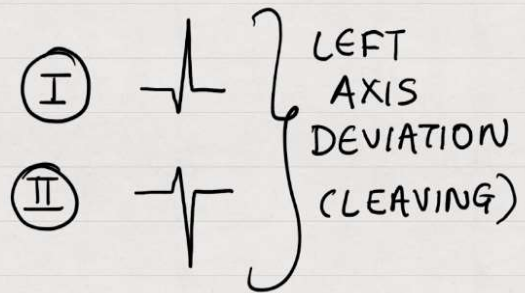

AXIS 1



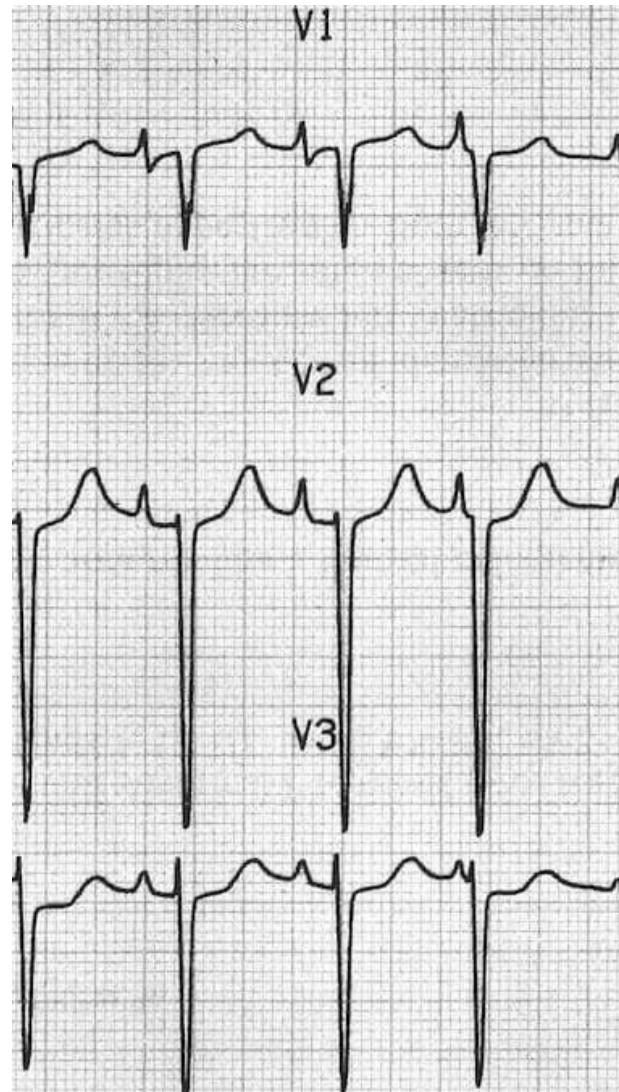
AXIS

ECG axis determination by Medicowesome

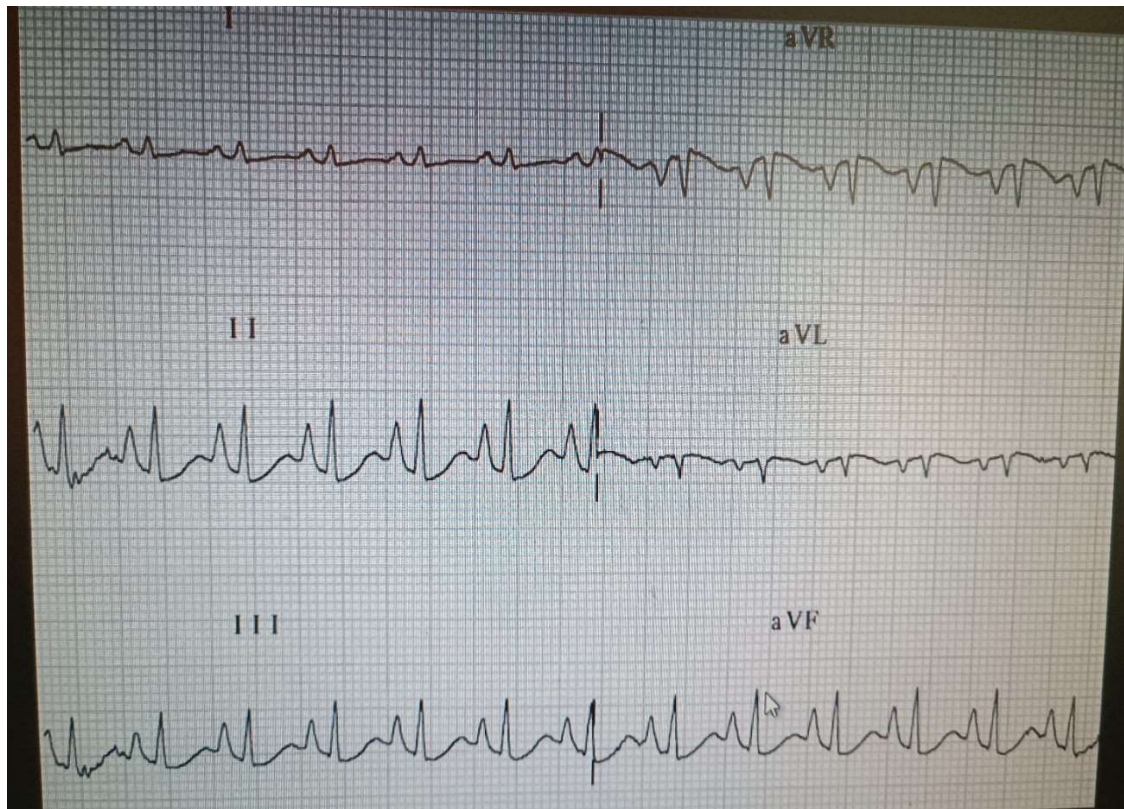2014

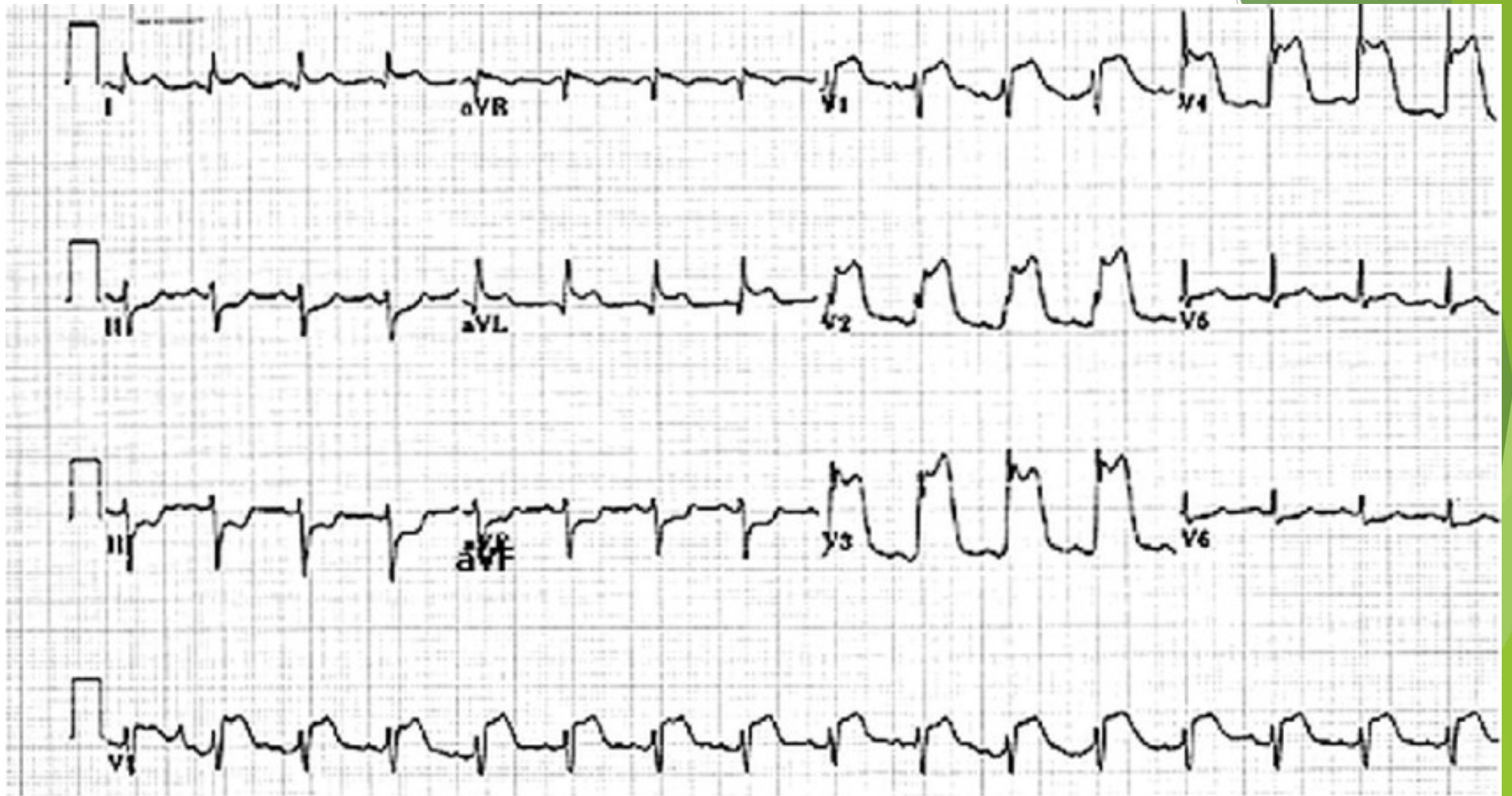


P-pulmonale 2

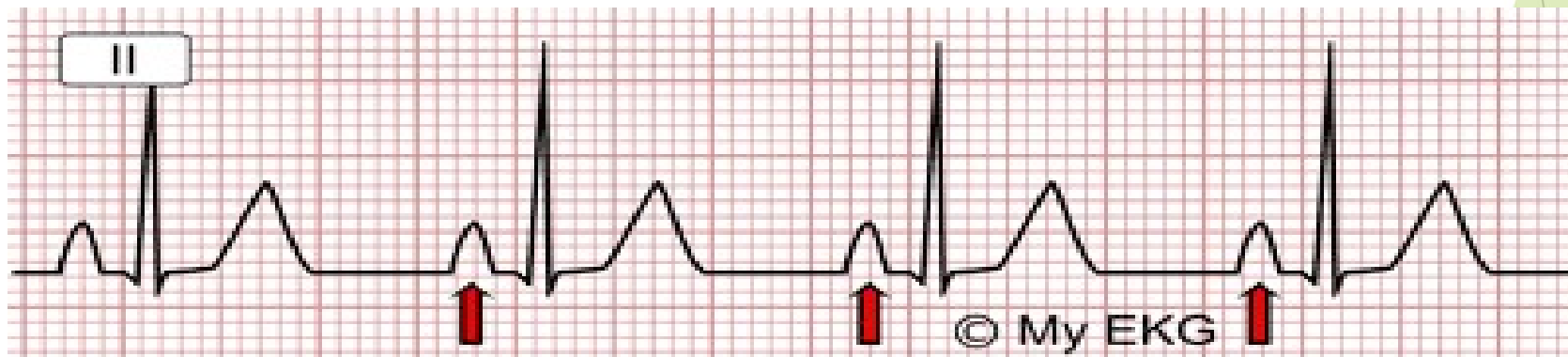
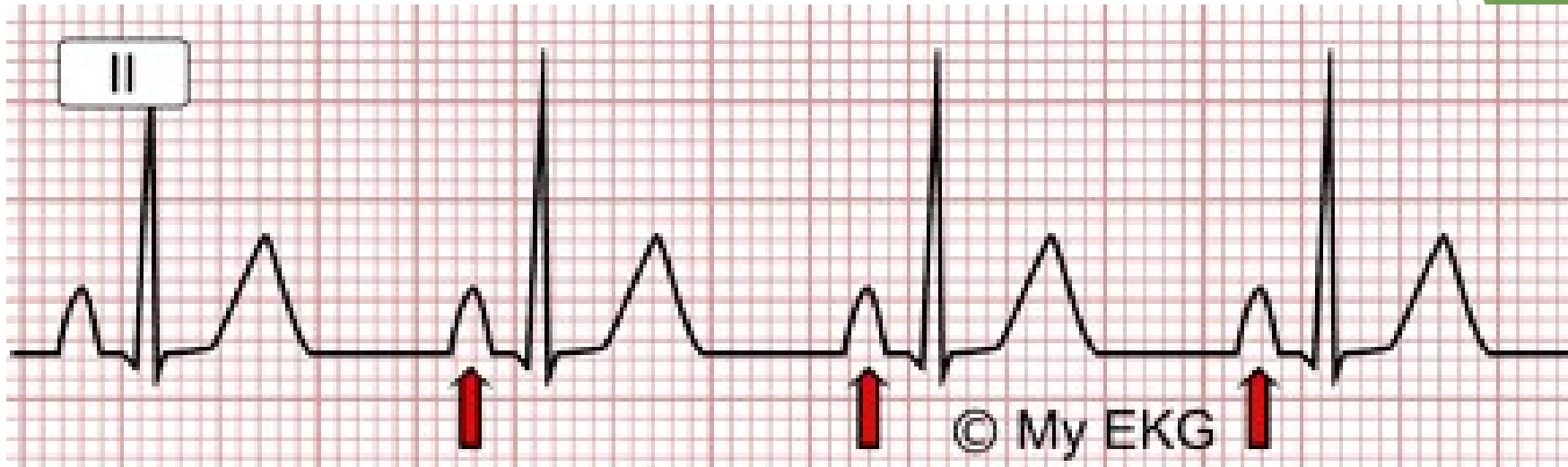


P PULMONAR1

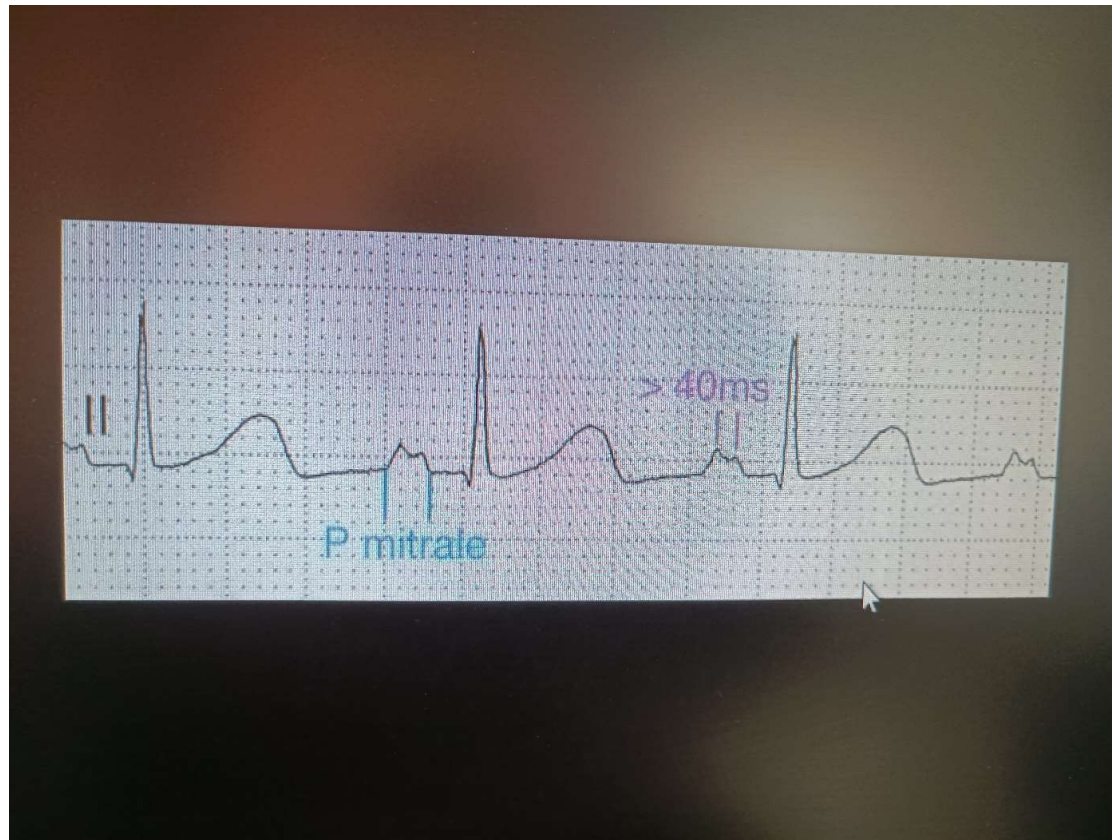




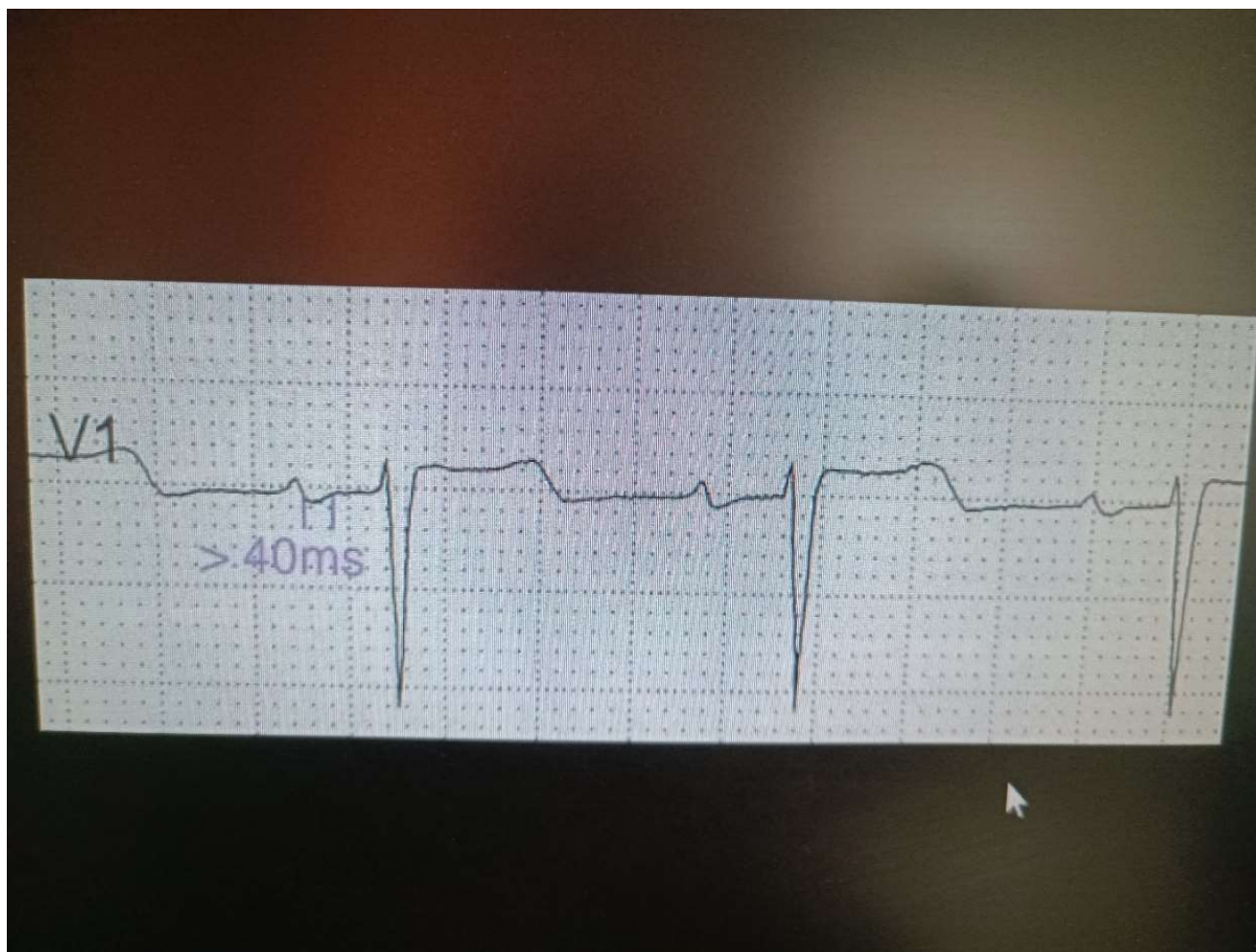
P PULMONAR



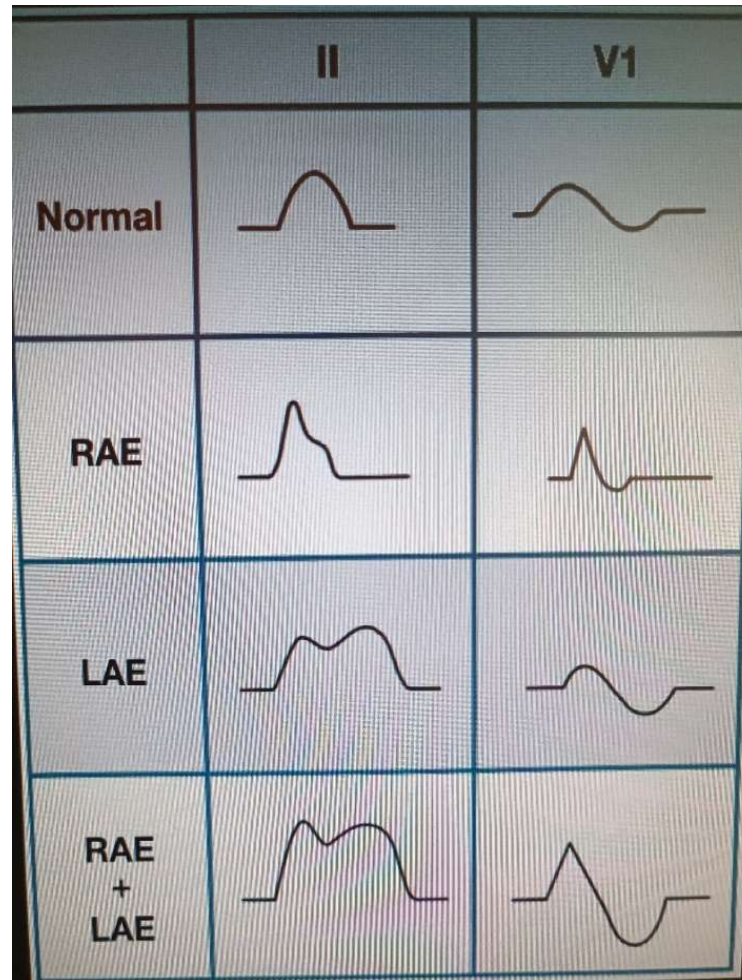
P MITRALE



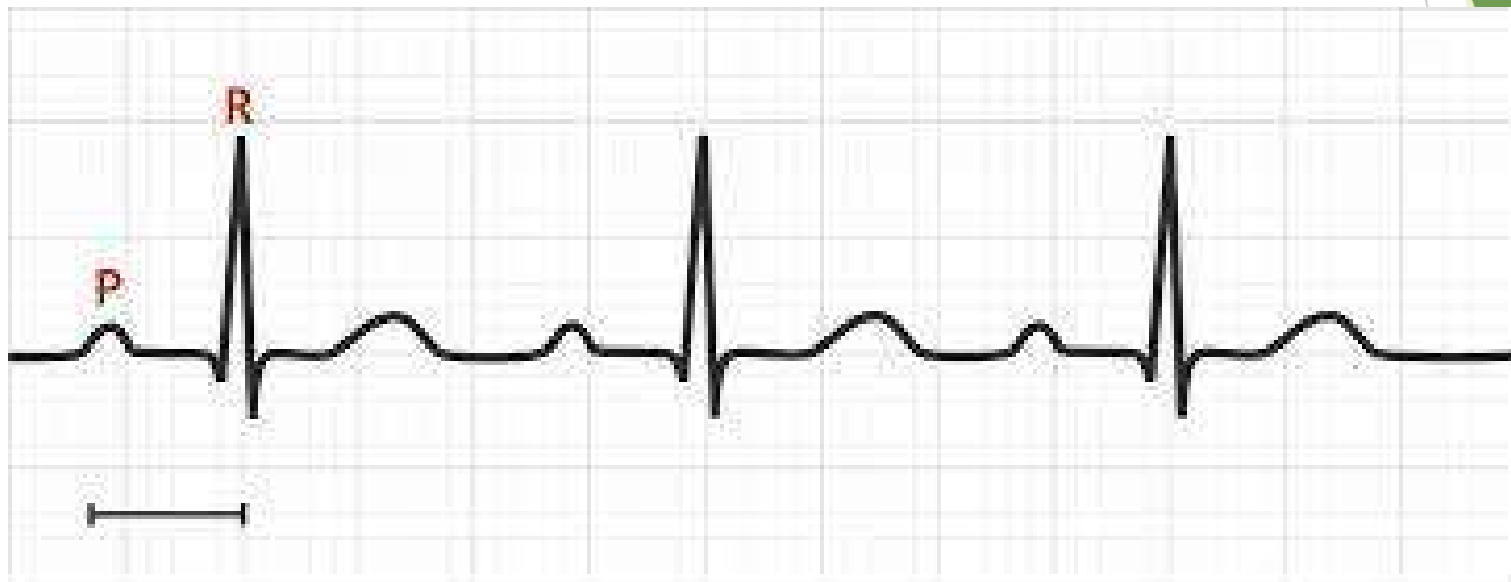
P MITRALEY



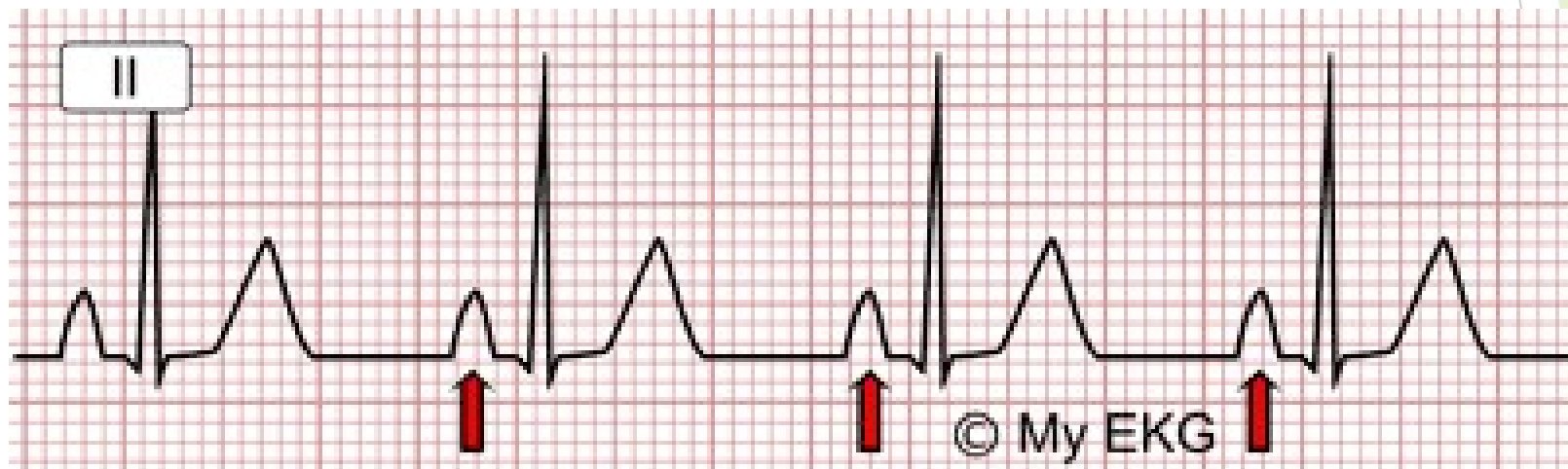
P ABNORMALITY



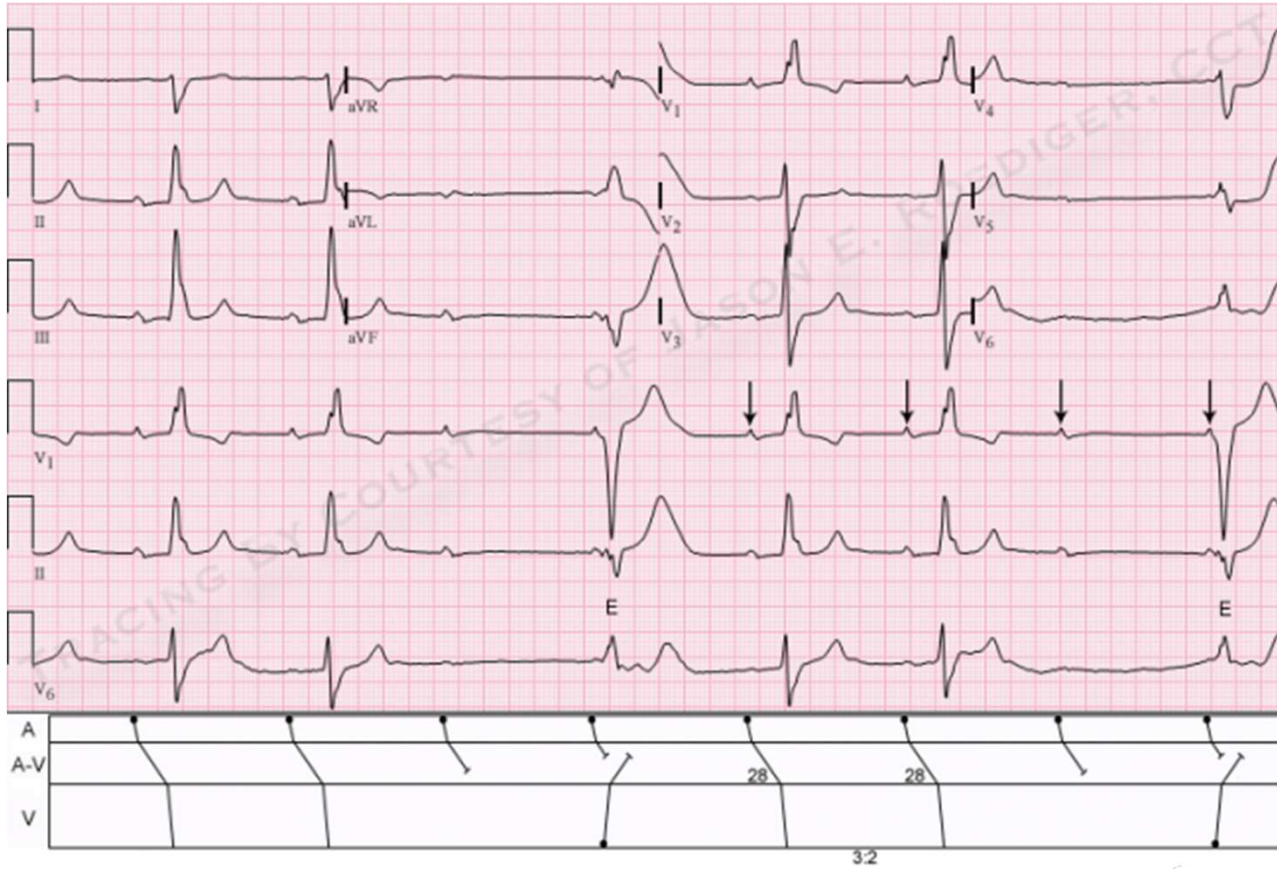
PR



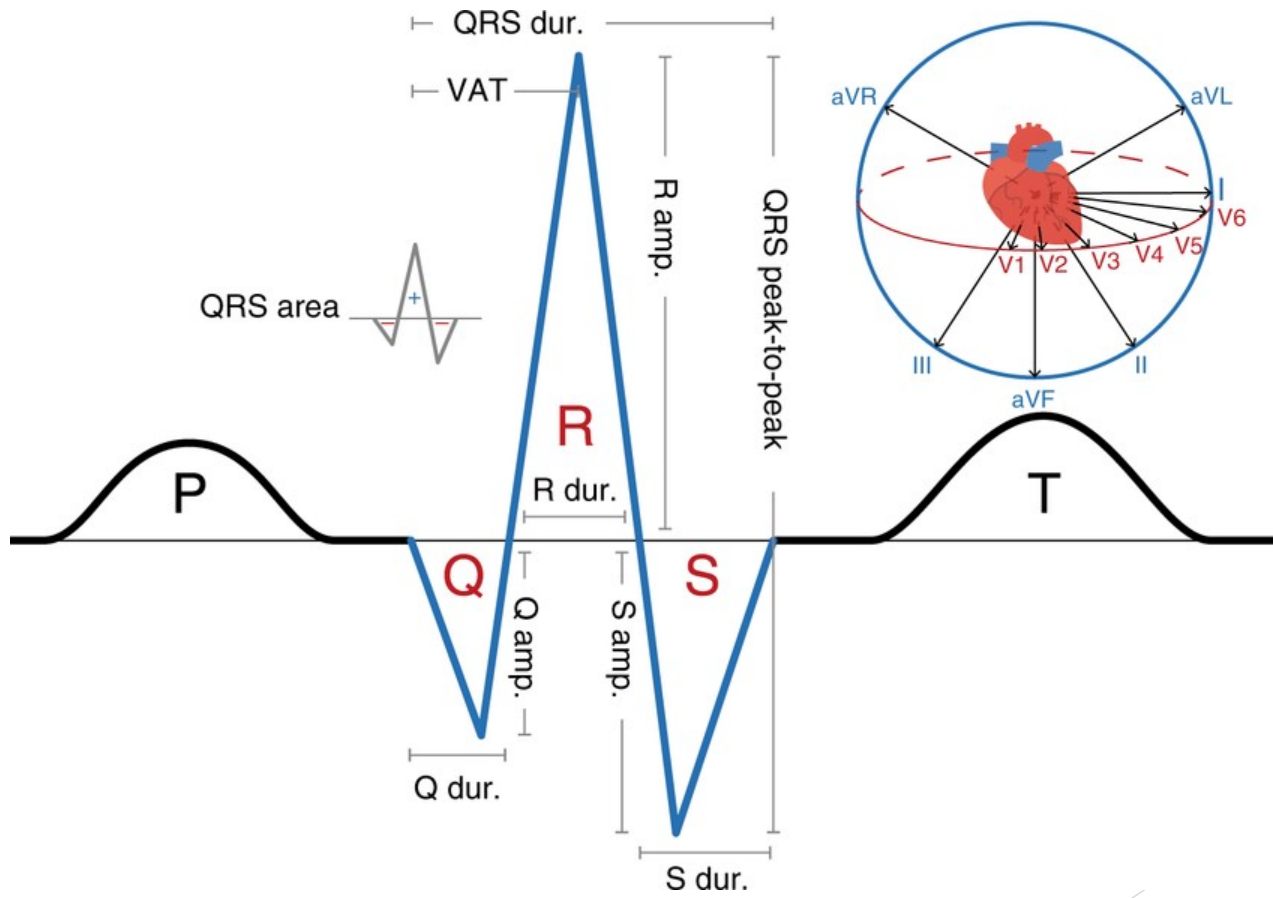
P pulmonar



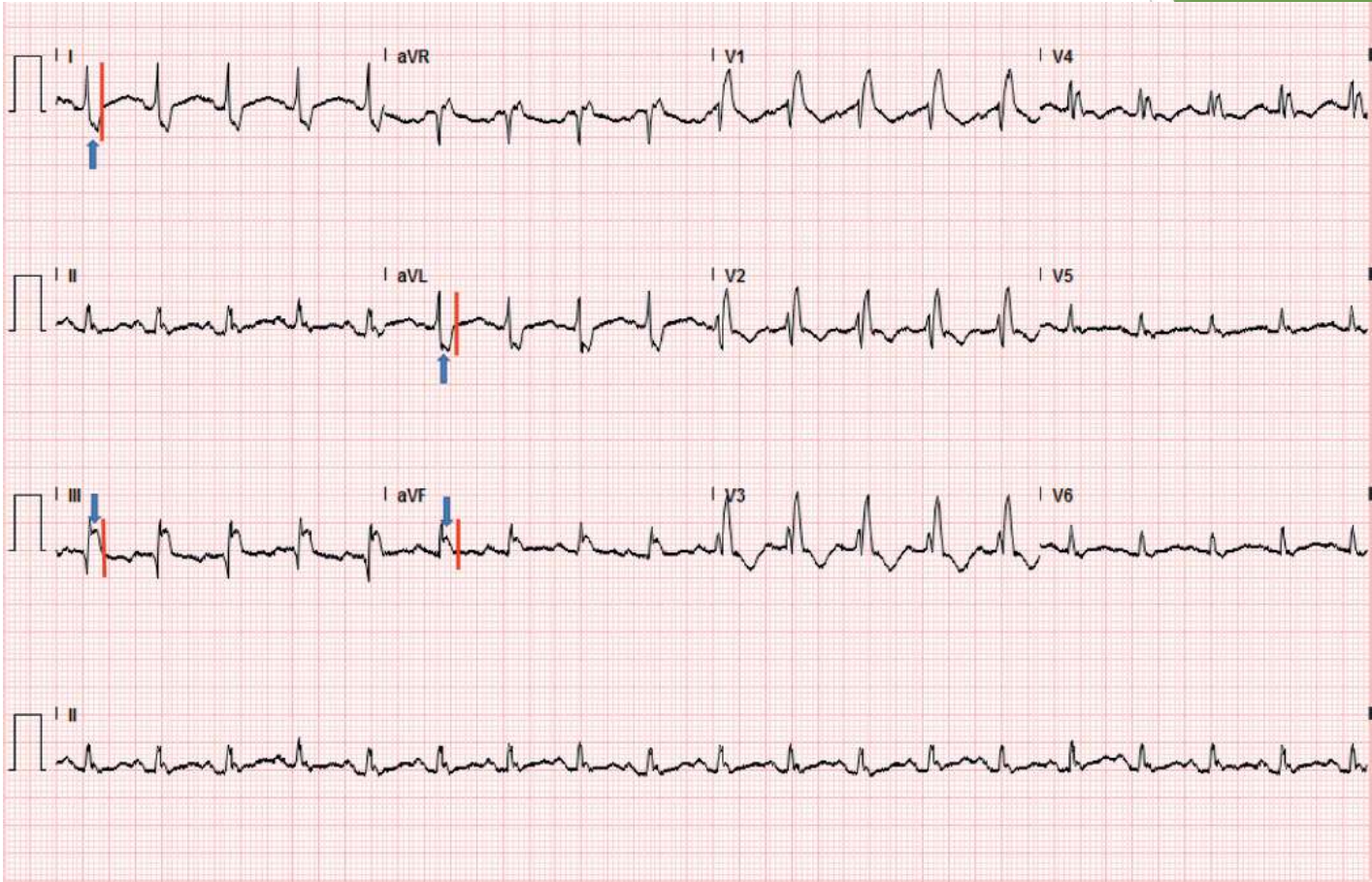
PR2



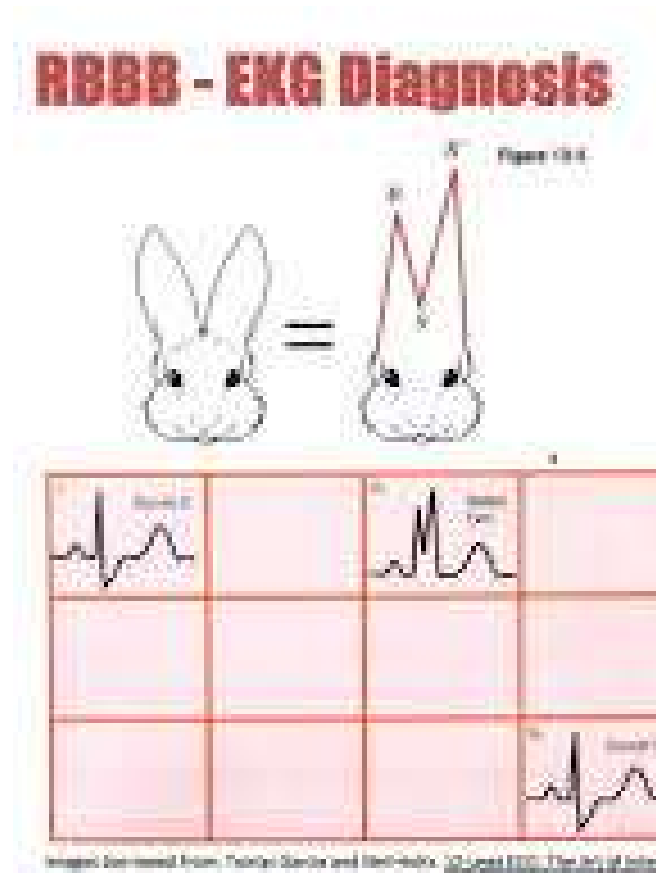
QRS



RBBB

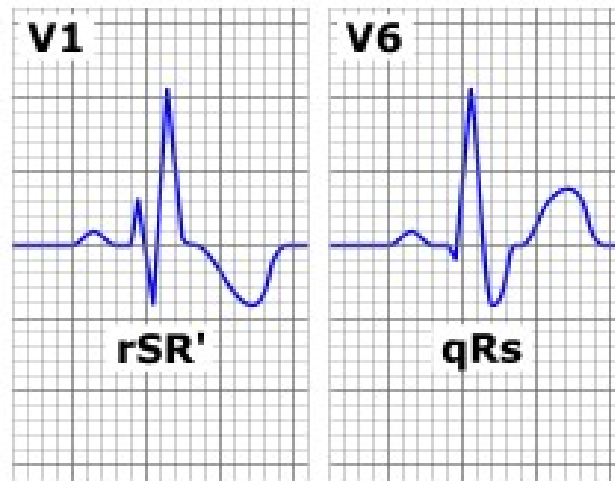


RBBB2

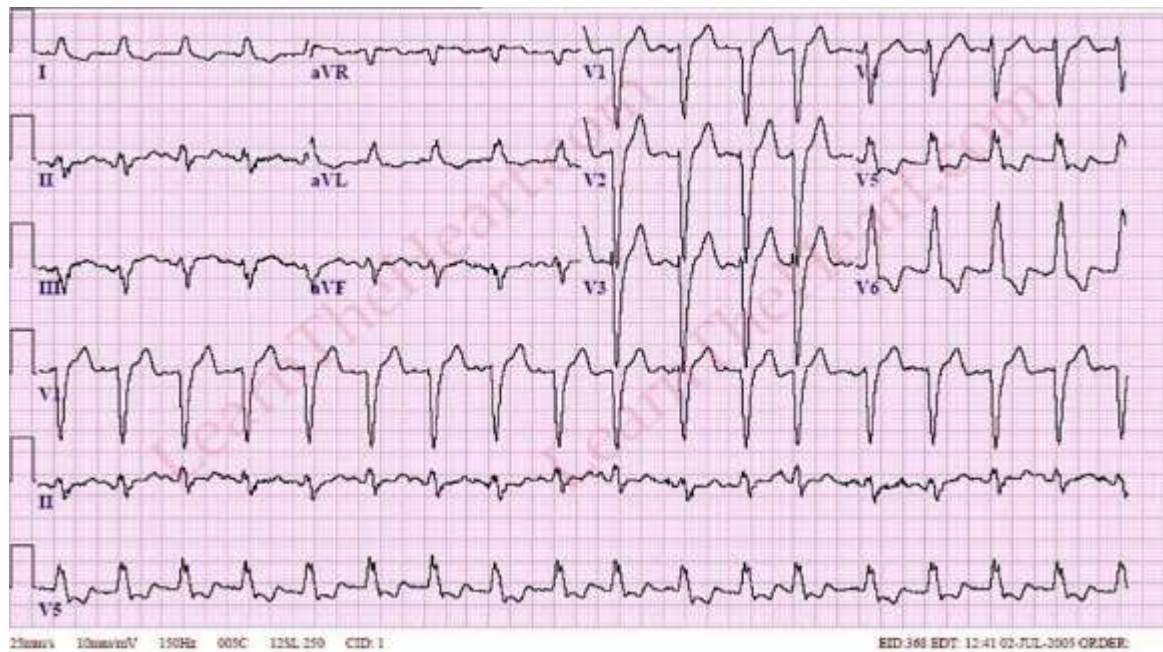


RBBB4

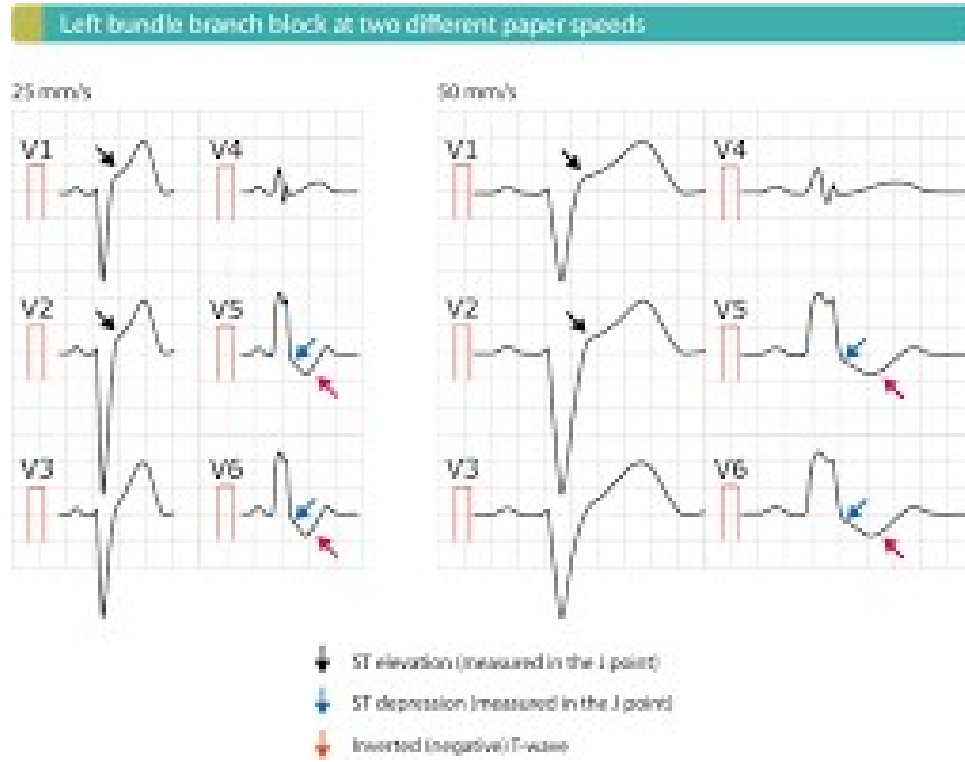
Right bundle branch block characteristics



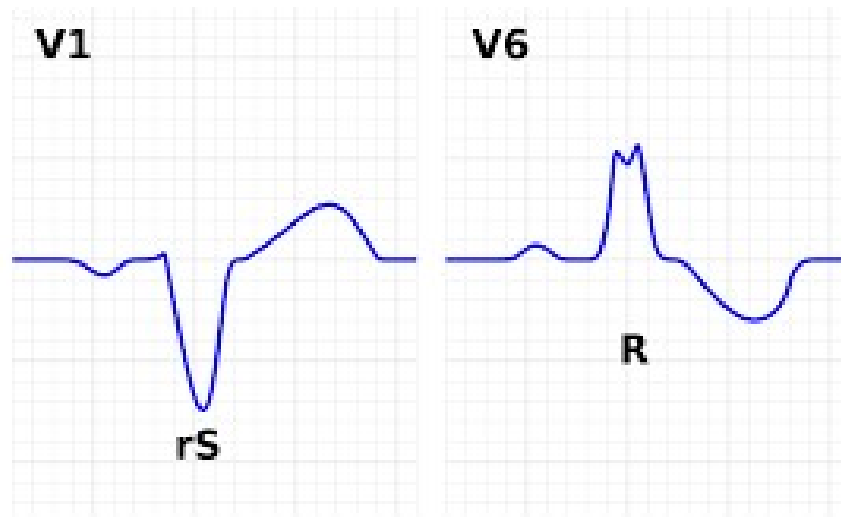
LBBB1



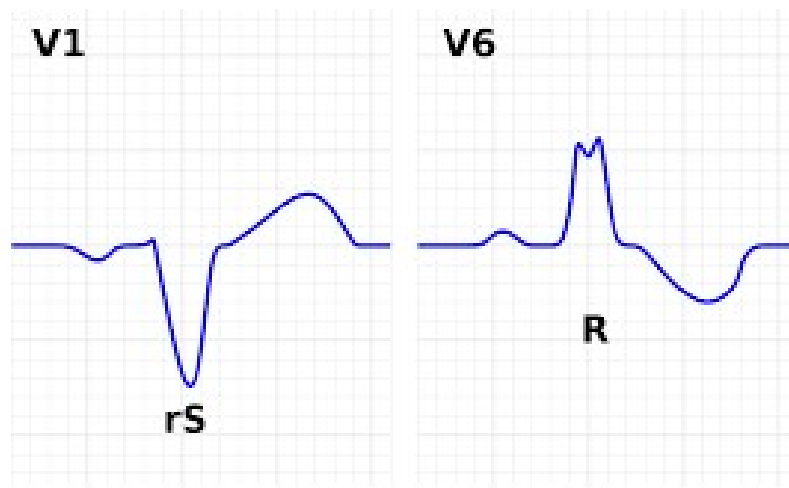
LBBB2



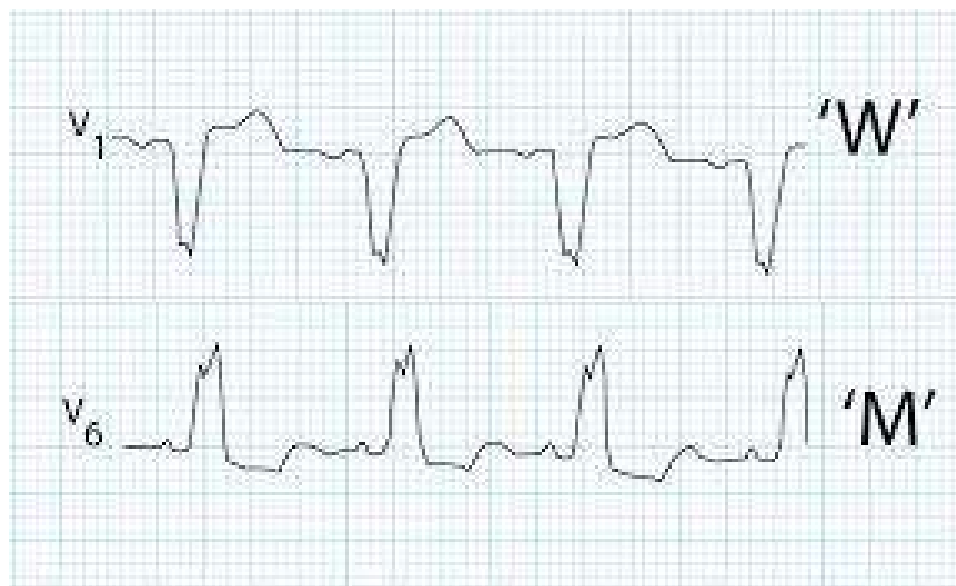LBBB3



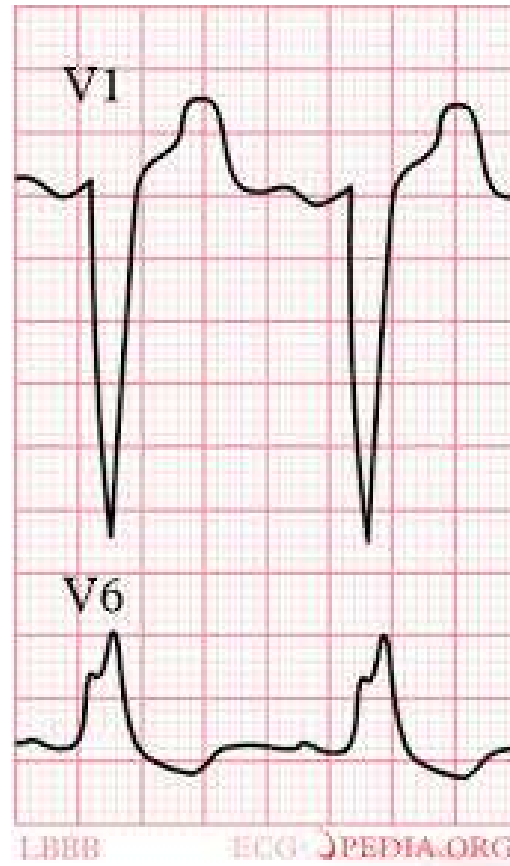LBBB4



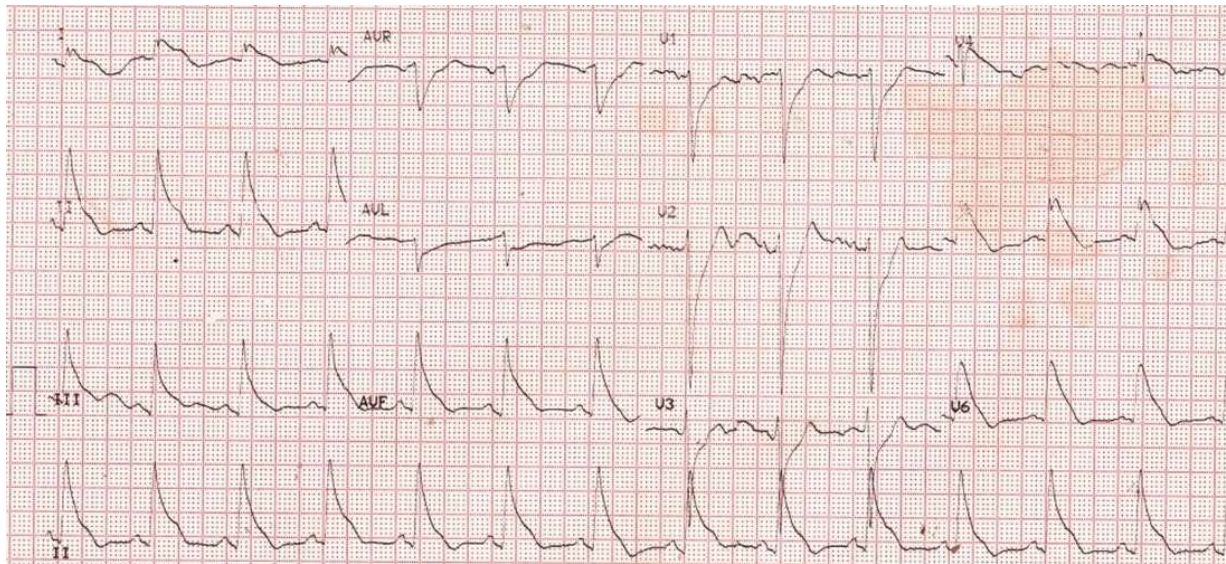
LBBB5



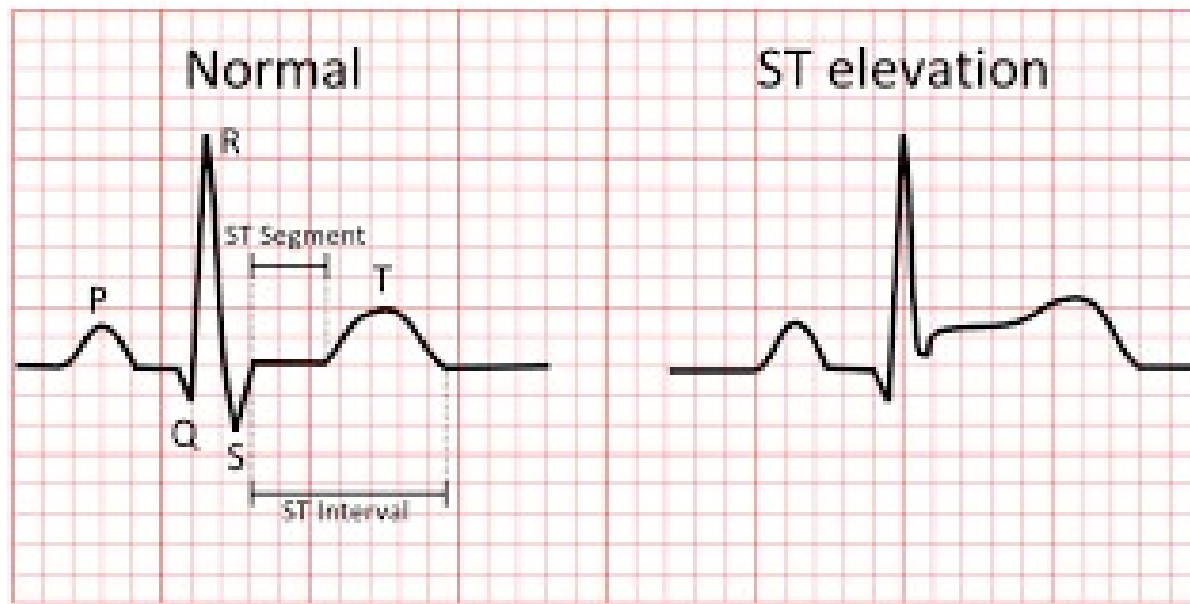
LBBB6



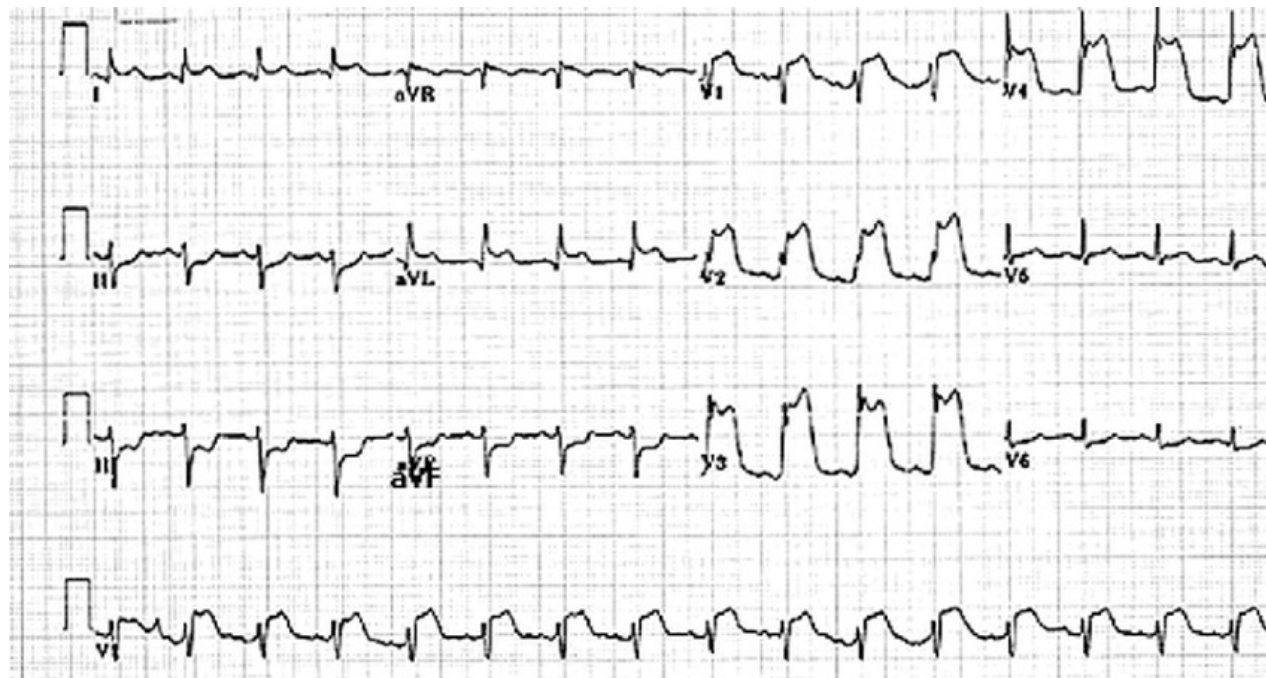
VERY WIDE QRS



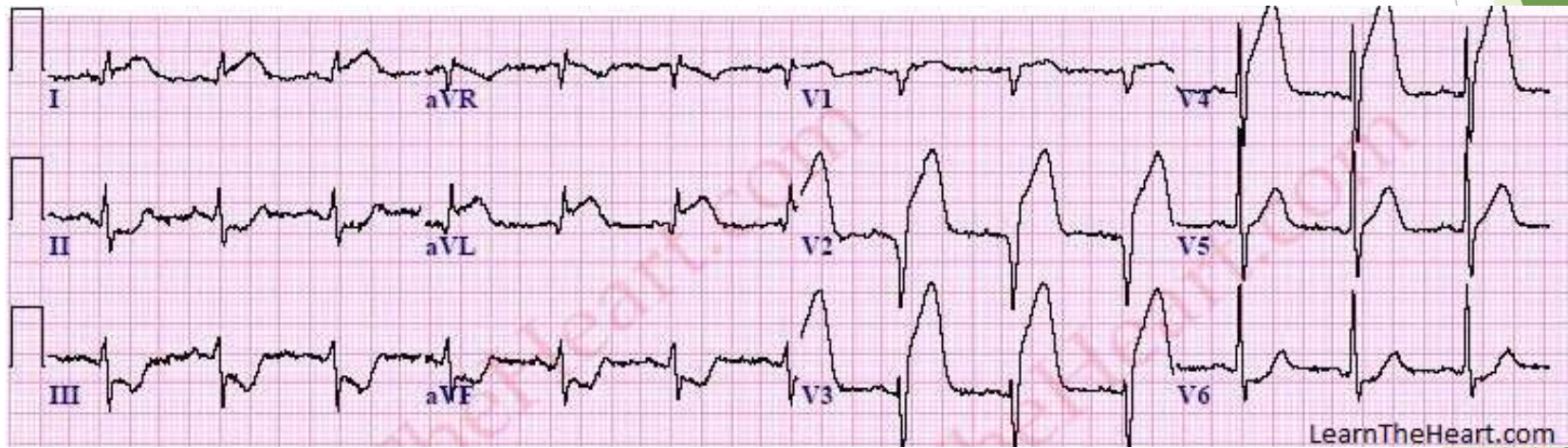
STE



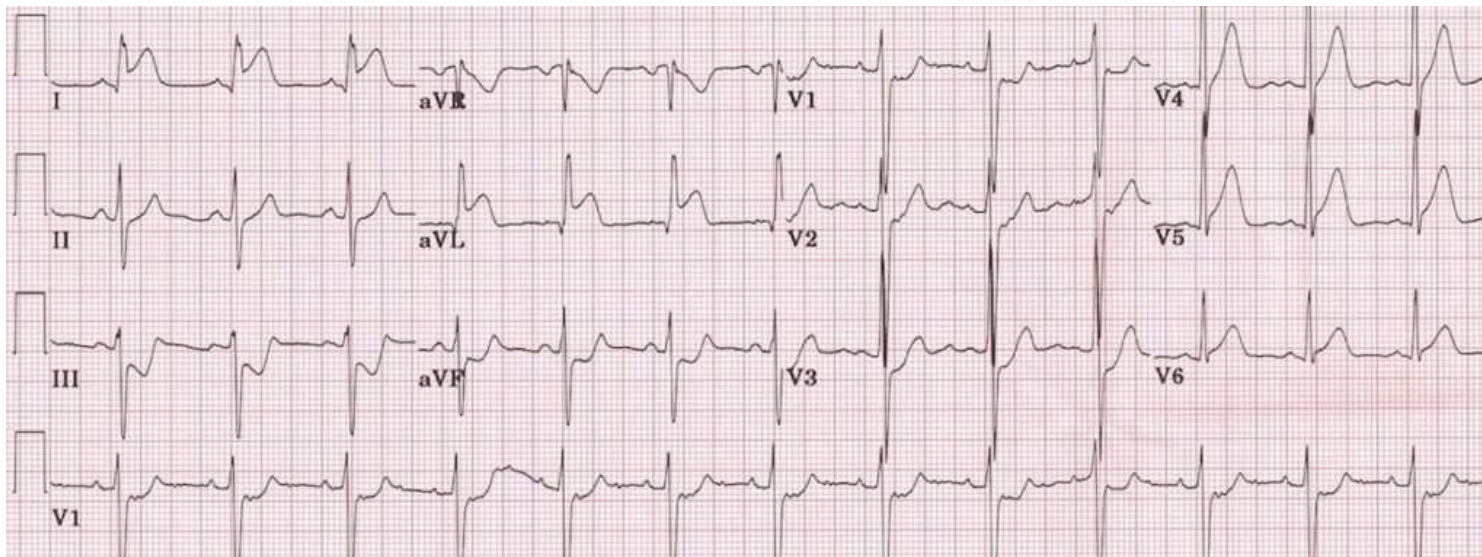
ANT MI



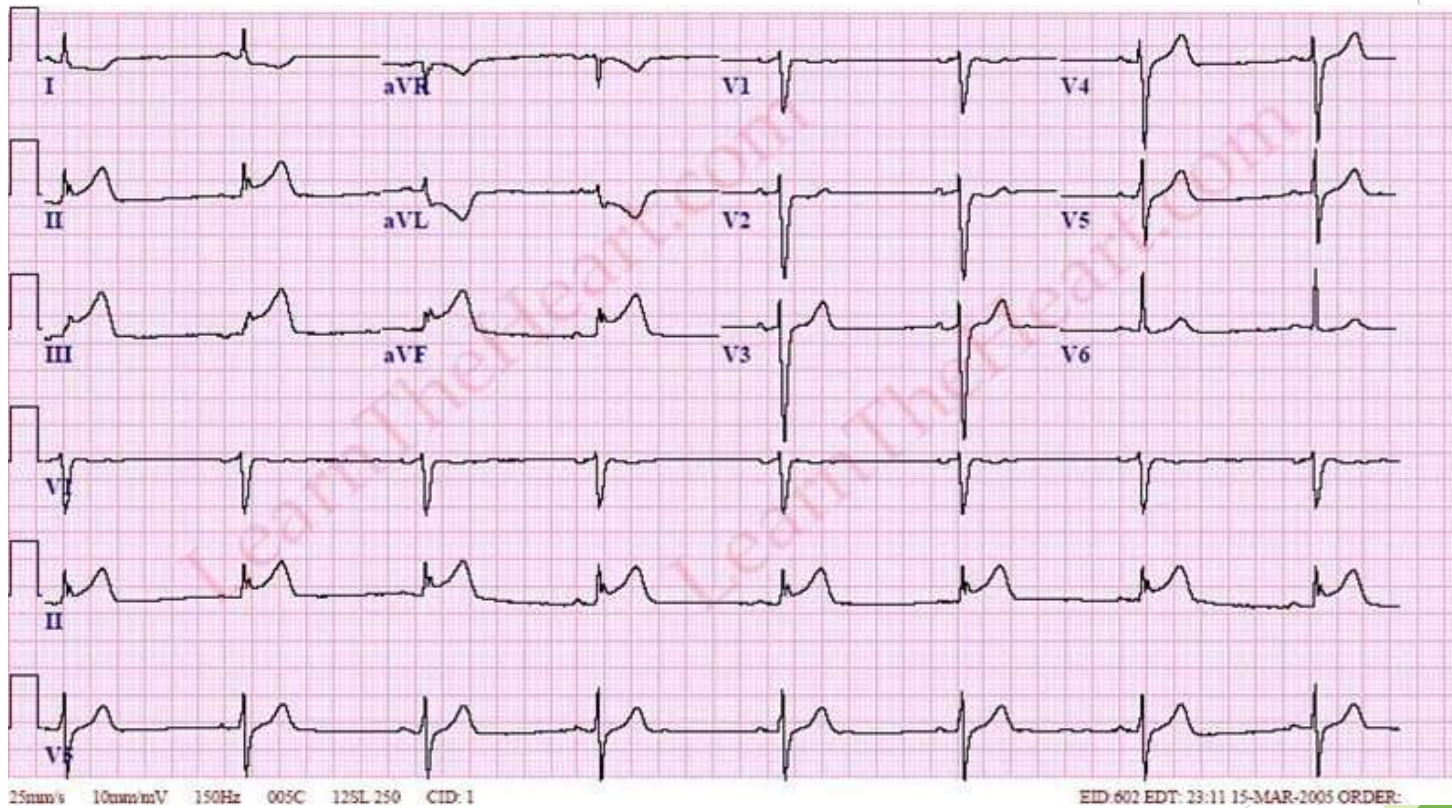
ANTEROSEPTAL MI



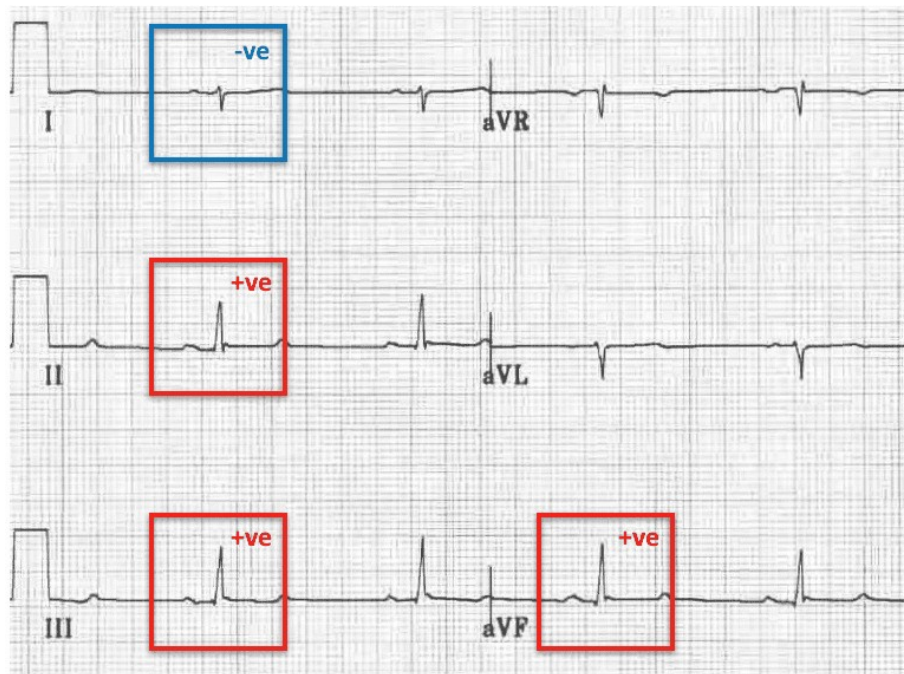
LATRAL MI



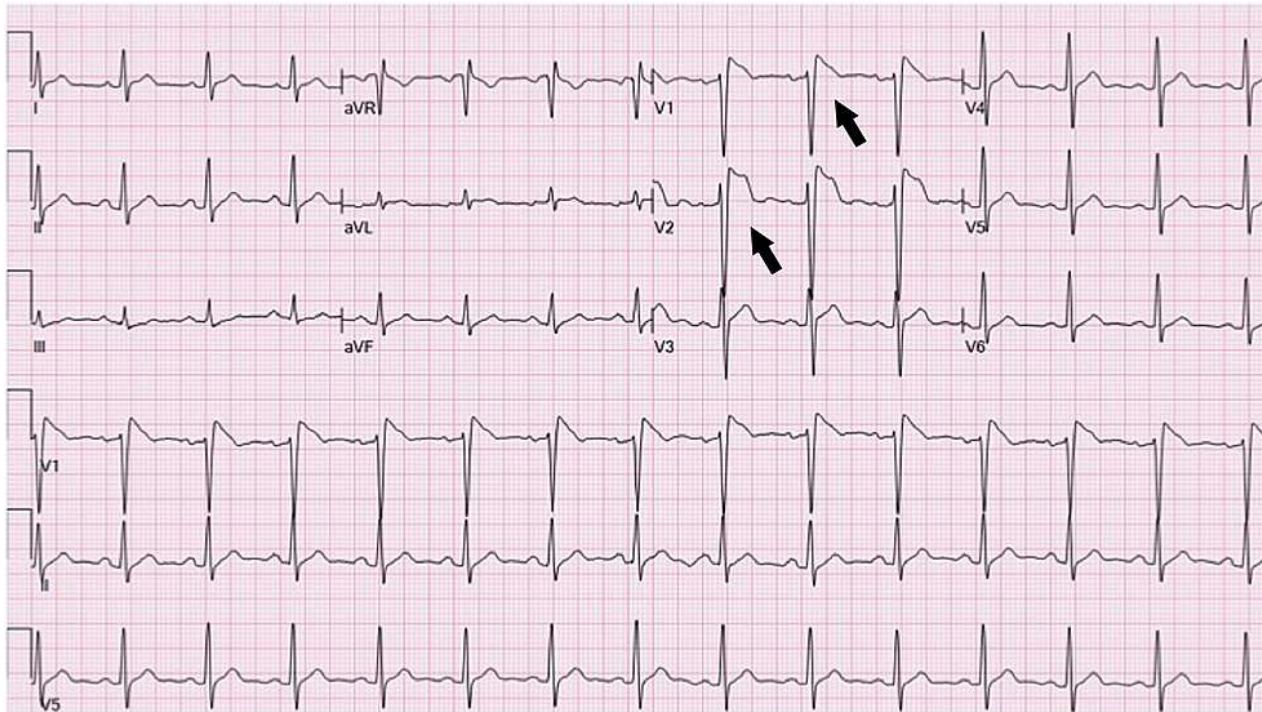
INF MI



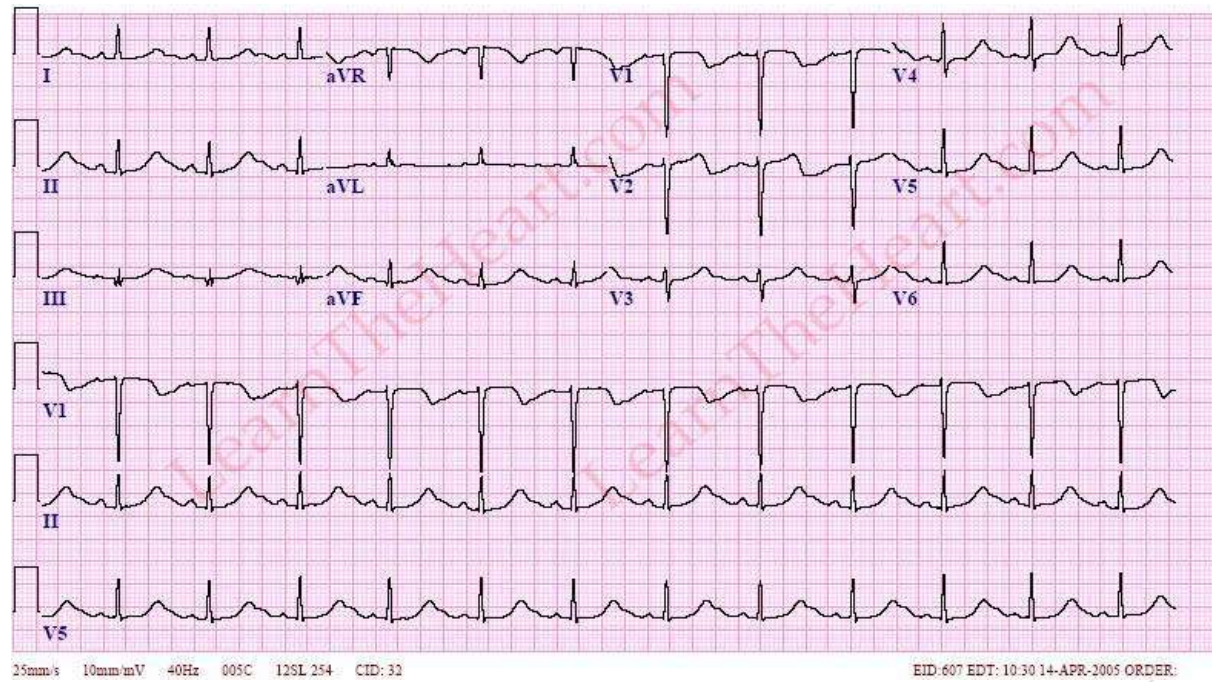
Left-Posterior-Fascicular-Block-LPFB- Right-axis-deviation



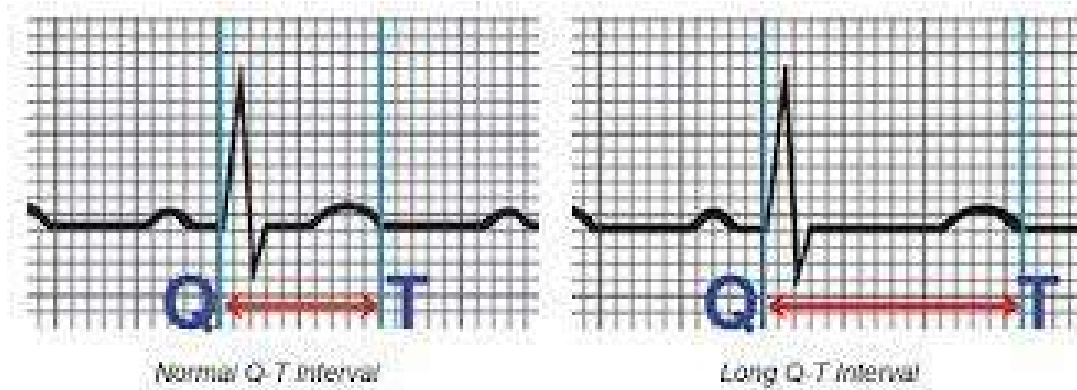
SEPTAL MI



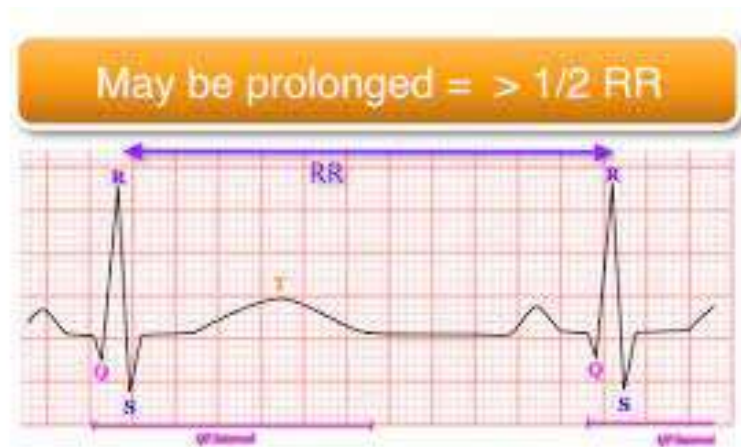
LONG QT



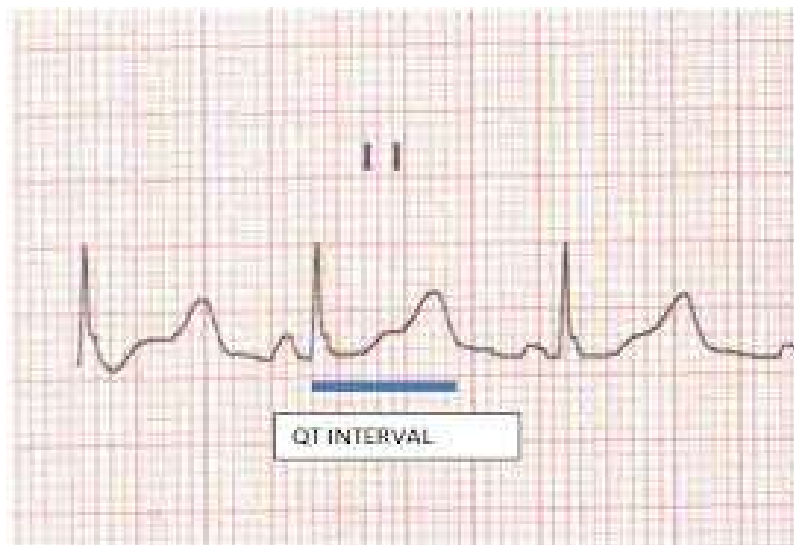
LONG QT 2



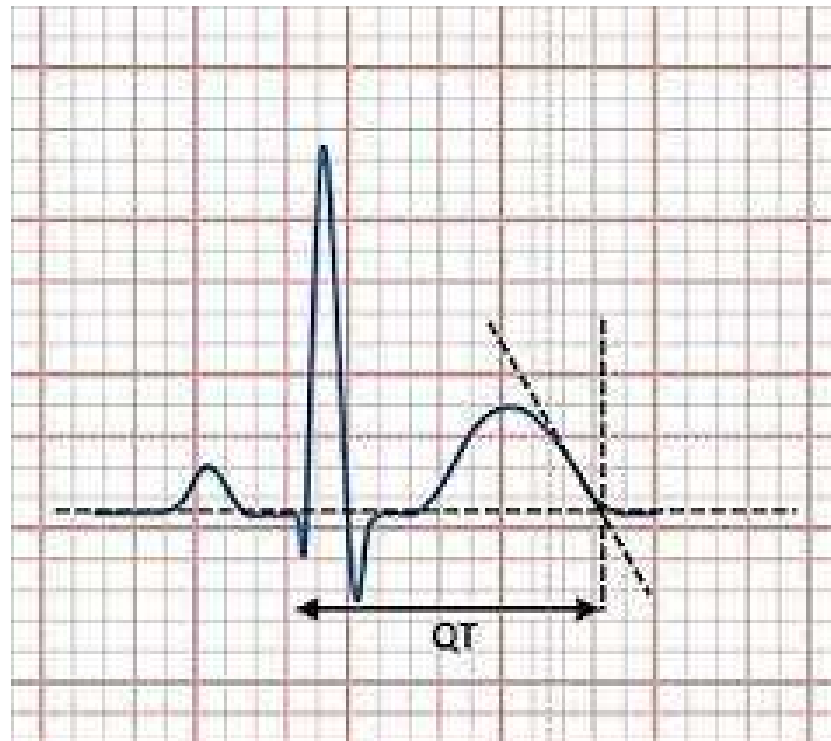
LONG QT3



LONG QT5

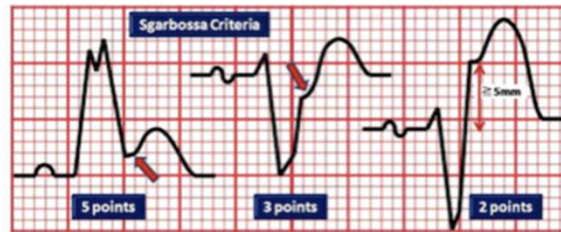

LONG QT6



Sgarbossa

Sgarbossa E et al.
 Electrocardiographic
 Diagnosis of
 Evolving Acute
 Myocardial Infarction
 in the Presence of
 Left Bundle-Branch
 Block. NEJM 334:
 481-7



	ST Segment Elevation \geq 1 mm Concordant with the QRS Complex	ST segment depression \geq 1 mm in lead V1-3	ST segment elevation \geq 5 mm and discordant with the QRS complex
Sensitivity	73%	25%	31%
Specificity	92%	96%	92%
(+) LR	9.13	6.25	3.88
(-) LR	0.29	0.78	0.75